

Envenomation of *Trimeresurus flavoviridis*

Venom and its Components, Phospholipase A2 Isozymes

Motoo KITANO,^{1*} Masato HIRANO,¹ Makoto YAHATA,¹
Eri UMEMURA,¹ Aichi YOSHIDA,² Shosaku HATTORI,³
Naoko UEDA,⁴ Daisuke TSURU,⁵ Motonori OHNO⁴

Abstract

The lesions caused by sublethal doses of *Trimeresurus flavoviridis* (*Tf*) venom injected into the anterior thigh muscle (quadriceps femoris muscle; QFM) of rats were studied with paraffin sections. A dose of 50 µg of *Tf* venom produced a large area of necrosis in QFM together with neighboring muscles. Phagocytosis of necrotic remnants was followed by marked regeneration of the muscle fibers. Myonecrosis was microscopically evident 30 minutes after the injection, and over the following 72 hours the necrotic muscles remained acellular and devoid of inflammatory reaction except at the very edge where liquefaction necrosis associated with inflammatory infiltrate was marked from the beginning. Blood vessels within and outside the necrotic foci were often involved in inflammatory changes and thrombosis, to some degree. However, marked hemorrhage was never noted in and around the foci. Phagocytosis of debris proceeded from the periphery, and after 24 hours the periphery of the necrotic foci was replaced by granulation tissue containing many regenerating myoblastic cells. Abscesses developed in the vicinity of the injection site in several rats receiving the crude venom, but never after injection of its phospholipase A2 isozymes, BPI or BPII. Muscle necrosis after envenomation of *Tf* venom seems due primarily to direct action of the venom, though vascular thrombosis and ischemia may contribute. Interestingly, in the rats, the myonecrotic *Tf* venom itself may cause marked and extensive activation of muscle fiber regeneration, and the venom seems to be a great myotoxin but not a hemorrhagic toxin.

Key words: *Trimeresurus flavoviridis* (*Tf*), Envenomation, Snake venom, Myotoxin, Skeletal muscle, Quadriceps femoris muscle (QFM), Myonecrosis, Regeneration, Myoblast, Phospholipases A2 isozymes, Hemorrhage

Introduction

Envenomation of *Trimeresurus flavoviridis* (*Tf*) snake venom causes two main symptoms, one local and the other systemic in humans. The local symptoms are severe pain, swelling, hemorrhage and necrosis in compliance with the bitten extremity, result in permanent

rhage (HOMMA and TU, 1971).

We have examined the short term effects of the various components of *Tf* venom on rat skeletal muscle, quadriceps femoris muscle (QFM), with closer attention to impairment, necrosis and regeneration of muscle fibers, the latter occurring even at the earlier stages. Moreover, the rats have shown a strong resistance to hemorrhage by envenomation of *Tf* venom. Renewed interest in this venom has stemmed from our recent studies of its action on muscle and vascular wall of the rat and from its fractionation of the venom, which may shed light on the pathogenesis of local lesions caused by the snake bites.

Materials and Methods

Venom and its phospholipase A2 isozymes

Tf venom was collected in Amami-Oshima island and lyophilized. Its phospholipase A2 (PLA2) isozymes, [Asp49] PLA2, BPI and BPII, the latter two being [Lys49] PLA2s, were separated by conventional chromatographies at Sojo University (LIU *et al*, 1990; KIHARA *et al.*, 1992). The crude venom and PLA2 isozymes were weighed and dissolved in sterile physiological saline immediately prior to use.

Rats

Young adult female and male rats (80-100g) of F344 (Charles River Japan, Inc.), Dark-Agouti (Shizuoka Laboratory Animal Center), Wistar/Furth (maintained in our laboratory by sister-brother mating) strains were divided into two to five groups, each group consisting of 6 rats (total; 90) (Table 1).

Experimental procedures

The rats of the first four groups were anesthetized with pentobarbital sodium (Nembutal: Abbot Lab, U.S.A.). The crude venom and three PLA2 isozymes (50 µg each) in 100 µl physiological saline were injected into each rat of four groups at the upper two-thirds of the right QFM. The fifth group, the control rats, were similarly injected with 100 µl sterile physiological saline.

The animals were allowed to survive for the periods ranging from 30 minutes to 72 hours and were sacrificed under ethyl ether anesthesia. Both the right and left hindlimbs and visceral organs including the brain were immersed for several days in 10% buffered

Of snake (Tf)	Duration	(F344 , DA, WF : f+m ^{**})	Necrosis	Inflammatory infiltration	Hemorrhage	Edema	Muscular regeneration	Inflammatory infiltration	Changes in the vascular walls ^{****}	Hemorrhage	Edema	Others
Crude Venom	30m	6	- ~ +	-	- ~ +	+	-	-	-	-	+	-
	6h	6	+	+	- ~ +	+	-	- ~ +	-	-	+	-
	24h	6	++ ~ +++	+++	- ~ +	++	+	++	- ~ +(Th)	- ~ +	++	-
	48h	6	++ ~ +++	+++	- ~ +	++	++	++	- ~ +(Th)	- ~ +	++	+
	72h	6	++ ~ +++	++	- ~ +	++	++	++	- ~ +(Th)	- ~ +	++	+
	Total	30										
[Asp49] PLA ₂	24h	6	++	++	- ~ +	++	+	++	- ~ +(Th)	-	++	-
	48h	6	++	++	- ~ +	++	+	++	-	-	++	-
	Total	12										
BPI	24h	6	++	+ ~ ++	- ~ +	++	+	+	- ~ +(Th)	-	++	-
	48h	6	++	+ ~ ++	- ~ +	+	++	+	- ~ +	-	+	-
	Total	12										
BPII	24h	6	++	+ ~ ++	- ~ +	+	++	+	- ~ +	-	++	-
	48h	6	++	+ ~ ++	- ~ +	+	+++	+	+	-	++	-
	72h	6	+	+	- ~ +	+	+++	+	-	-	++	-
	Total	18										
Control (physiological saline)	30m	6	-	-	-	-	-	-	-	-	-	-
	24h	6	-	-	-	-	-	-	-	-	-	-
	48h	6	-	-	-	-	-	-	-	-	-	-
	Total	18										

kinds of toxins, among three strains of rats and among female and male rats, so we preferred to describe here all together.

Macroscopically, there was a more or less marked necrotic change with a mild swelling of the muscle mass in the venom-injected right hind leg. A close examination of injected QFM revealed an absence of marked hemorrhage (Fig 1).

Histologically, the muscle tissue injected with physiologic saline solution had a typical histology of skeletal muscle with no abnormality in muscle fibers, nerves or blood vessels.

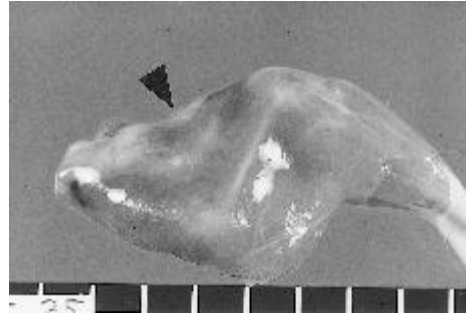


Fig. 1: A large necrotic lesion in the QFM of a F344 male rat 48 hours after the inoculation of the crude venom of *Tf*. Note the severe and extensive atrophy of the skeletal muscles of the anterior thigh due to necrotic changes without a marked hemorrhage.

There were groups of affected cells accompanied by the decrease of fine cytoplasmic structures to some degree, which were located in the periphery of the muscle as early as 30 minutes after inoculation. At this time edema without inflammatory cells were observed, and many of the skeletal muscle cells presented edematous swelling (Fig.2).

Necrosis of muscle fibers in QFM was indicated by nuclear pyknosis and fragmentation of the myofibrils into homogenous eosinophilic masses separated by empty-looking segments 6 hours after injection. There were many areas where necrotic cells predominated. Some of them appeared to be in the initial stages of cell degeneration, i.e. some muscle cells had only edematous swelling, whereas other cells were in a more advanced stage of damage with the formation of dense clumps of myofibril alternating with cellular spaces apparently devoid of myofibrillar material. The findings support the view that the earliest alterations seem to take place in the periphery of the necrotic focus. A very mild inflammatory infiltrate was observed at this time.

granulation tissue with neutrophils, macrophages and fibroblasts surrounded the central mass of necrotic fibers. Myofibrillar material in affected cells was pale and amorphous. Very little fibrosis was observed.

Simultaneously, regenerative proliferation of myoblasts, which were characterized by the presence of myofibrils and rows of centrally-located nuclei, were observed in the periphery of necrotic cells. The activity of proliferation of small regenerating muscle fibers were seen most markedly in BPII group, and in the BPI, crude venom, and [Asp49] PLA2 groups in descending order of degree. Twenty-four hours after toxin inoculation, the regenerating cells were spindle in shape with scanty basophilic cytoplasm and a central nucleus, some revealing mitotic activities at 24 hours (Fig.3). Muscle regeneration was observed in the peripheral fibers of necrotic muscles, but the inner parts of those muscles appeared still necrotic. The regenerating cells gradually became hypertrophic with an acidophilic light cytoplasm at 72 hours (Fig.4). The muscle tissue examined histologically 8 weeks after the onset of muscle necrosis was characterized by the presence of abundant


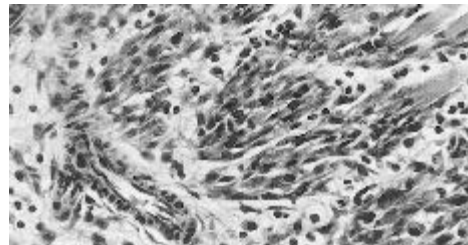


Fig. 2: Massive necrosis of the QFM of a F344 male rat 48 hours after the inoculation of the crude venom of *Tf*. Marked inflammatory infiltration is focally seen in the necrotic layer, most of which is composed of liquefaction necrosis and partly coagulative necrosis. Hemorrhage is negligible.



normal, but in some animals inflammatory infiltrate was noted in the vascular walls and platelet thrombi were found in some medium-sized veins and arteries, occasionally forming occlusive masses (Fig.5). There were several peripheral nerves showing marked edema of the endoneurium, but no apparent structural disintegration was found.

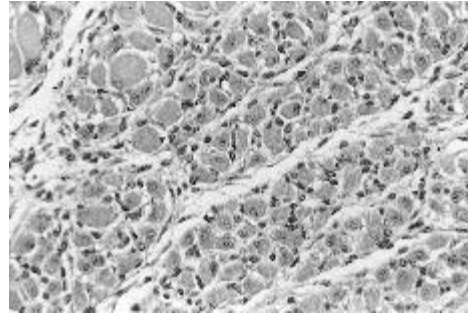


Fig. 4: Numerous myoblastic cells around the necrotic focus in a F344 male rat 72 hours after inoculation of the BPII. Myoblastic cells are hypertrophied and have a round nucleus in their central cytoplasm. Some of the regenerating cells have two nucleoli.

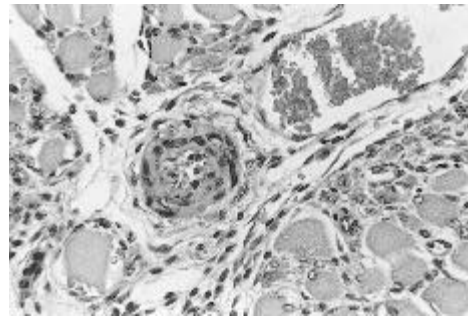


Fig. 5: Thrombosis of a medium-sized vessel in the peripheral area of a necrotic focus in a F344 female rat 48 hours after inoculation of the crude venom. In the wall of the vessels inflammatory infiltrate is observed.

Discussion

Thirty minutes after the injection of *Tf* venom, initial changes of muscle fiber necrosis was

delay in phagocytosis was also observed after the inoculation of venom of other snakes, and vasculitis and thrombosis were also considered important in its pathogenesis. Similar vascular changes were reported after the local administration of various other snake venoms (HOMMA and TU, 1971).

On the other hand, muscle necrosis by the local inoculation of various kinds of snake venoms is usually followed by the rapid phagocytosis of debris at the periphery of the necrotic area. The clearing of necrotic material by phagocytes was followed by a rapid regeneration process. Myoblasts were observed 24 hours after the onset of myonecrosis, and by 8 weeks regeneration was complete (data, not shown). There were many regenerative cells of size similar to that of adult muscle fibers, but with the centrally-located nuclei, a typical finding in regenerating muscle cells. The success of regeneration after myonecrosis induced by *Tf* myotoxin might be due to the fact that neither nerves nor blood vessels are markedly affected by this toxin, since adequate blood supply and innervation are essentially requirements for muscle regeneration (QUEIROZ *et al.*, 1984; GUITIERREZ *et al.*, 1989).

The most striking effects produced by the parenteral injection into animals of many snake venoms, including venom of *Tf*, are local, consisting of marked hemorrhage, myonecrosis, and edema (OHSAKA *et al.*, 1960; OKONOGI *et al.*, 1960; LOMONTE *et al.*, 1994). It is well known that the pathological signs characteristic of *Tf* bite in humans, rabbits and mice are marked by extensive hemorrhage and necrosis (OKONOGI *et al.*, 1960). Our experimented rats, however, failed to demonstrate that hemorrhage was a predominant sign of snake venom injection. We used three strains of rats and four kinds of preparations of *Tf* venom for our experiments. In spite of the difference of strains of rats and kinds of venom-preparations, we could not note marked hemorrhage in and around the injection area.

It is of great interest whether or not the same principle is responsible for necrosis and hemorrhage. However, little is known concerning this point. Many researchers stated that hemorrhage is due, at least in part, to the action of myonecrotic enzymes, such as phospholipase A2 (LOMONTE *et al.*, 1994). Concerning local hemorrhage, our results did not agree with the general view that snake venoms produce bleeding at the site of injection. Pathological observations indicated that the easily discernible local changes produced in the humans, rabbits and mice by *Tf* bite injury were hemorrhage. However, in the present experiment, *Tf* venom did not give rise to any prominent bleeding locally, but produced myolysis with edema, in the rats.

Some investigators have suggested that proteolytic enzymes are factors in hemorrhage and necrosis (OHSAKA *et al.*, 1960; OKONOGI *et al.*, 1960). Our observations concerning the

devoid of hemorrhagic activity, *elapidae* venoms, fail to cause significant changes in the arterial walls. The important changes responsible for developing arterial lesions appear to be the injury of the endothelium and the disintegration of the media. It has been reported that *Tf* venom attacks the endothelium and smooth muscles of the media when the venom is injected close to the arteries. This suggests that both hemorrhagic and myonecrogenetic factors play an important role in the involvement of local blood vessels (MATSUI *et al.*, 2000). Thrombi were observed in local arteries at the sites injected with several kinds of venoms. In our experiments the frequency of thrombus formation was not always in parallel with the severity of arterial lesions and of local hemorrhage and swellings. Important factors favoring thrombosis are slowing or eddying of the blood stream, injury to the lining of a blood vessel and alterations of the blood. If a longer period of time allowed to elapse between injection and autopsy, there would probably have been more thrombus formation, as *viperinae* and *crotalinae* venoms produce conditions favorable to this kind of lesions (HOMMA and TU, 1971).

Acknowledgements

This work was supported, in parts, by a Fund for Promotion and Development of Amami Islands sponsored by Ministry of Land, Infrastructure and Transport and Kagoshima Prefecture and a Kagoshima University Fund for Improvement of Education and Research Activities. Prof. Toru Aoyama kindly reviewed the manuscript.

References

- ESTEVAO-COSTA, M. I., DINIZ, C. R., MAGALHAES, A., MARKLAND, F. S. and SANCHEZ, E. F. 2000. Action of metalloproteinases mutalysin I and II on several components of the hemostatic and fibrinolytic systems. *Thromb. Res.* 99, 363-376.
- GUTIERREZ, J. M., CHAVES, F., GENE, J. A., LOMONTE, B., CAMACHO, Z. and SCHOSINSKY, K. 1989. Myonecrosis induced in mice by a basic myotoxin isolated from the venom of the snake *Bothrops Nummifer* (jumping viper) from Costa Rica. *Toxicon*, 27, 735-745.
- HOMMA, M. and TU, A.T. 1971. Morphology of local tissue damage in experimental snake

- LOMONTE, B., LUNDGREN, J., JOHANSSON, B. and BAGGE, U. 1994. The dynamics of local tissue damage induced by *Bothrops asper* snake venom and myotoxin II on the mouse cremaster muscle: an intravital and electron microscopic study. *Toxicon*, 32, 41-55.
- MANDELBAUM, F. R., SERRANO, S. M., SAKURADA, J. K., RANGEL, H. A. and ASSAKURA, M. T. 1989. Immunological comparison of hemorrhagic principles present in venoms of the *Crotalinae* and *Viperinae* subfamilies. *Toxicon*, 27, 169-177.
- MATSUI, T., FUJIMURA, Y. and TITANI, K. 2000. Snake venom proteases affecting hemostasis and thrombosis. *Biochim Biophys Acta.*, 1477, 146-156.
- OHSAKA, A., IKEZAWA, H., KONDO, H., KONDO, S. and UCHIDA N. 1960. Haemorrhagic activities of *Habu* snake venom, and their relations to lethal toxicity, proteolytic activities and other pathological activities. *Br. J. Exp. Pathol.*, 41, 478-486.
- OKONOJI, T., HOSHI, S., HOMMA, M., MITSUHASHI, S., MAENO, H. and SAWAI, Y. 1960. Studies on the *Habu* snake venom. 3-2. A comparative study of histopathological changes caused by crude venom, purified *Habu*-proteinase and other proteinases. *Jpn. J. Microbiol.*, 4, 189-192.
- QUEIROZ, L.S., SANTO-NEO, H., RODRIGUES-SIMIONI, L. and PRADO-FRANCESCHI, J. 1984. Muscle necrosis and regeneration after envenomation by *Bothrops Jararacussu* snake venom. *Toxicon*, 1984, 22: 339-346.